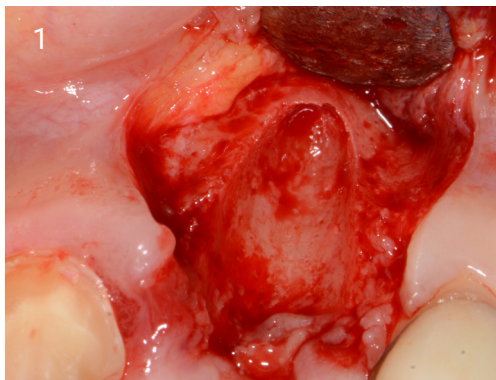
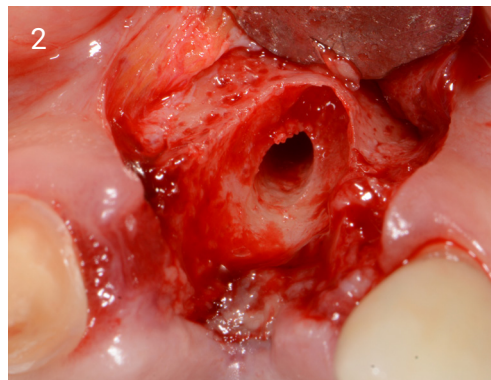


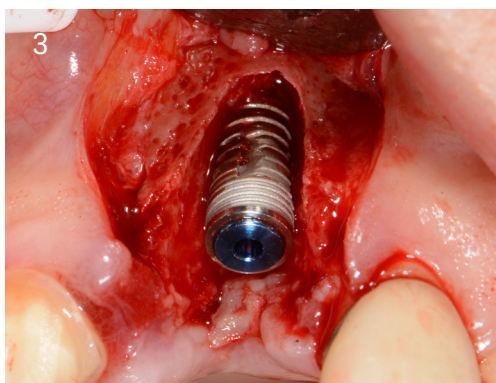UPPER LEFT CENTRAL CASE STUDY



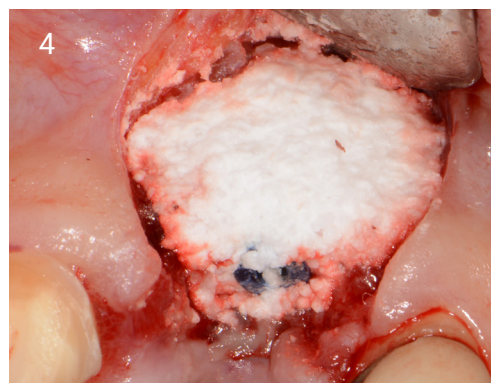1. Small flap raised to show buccal defect.



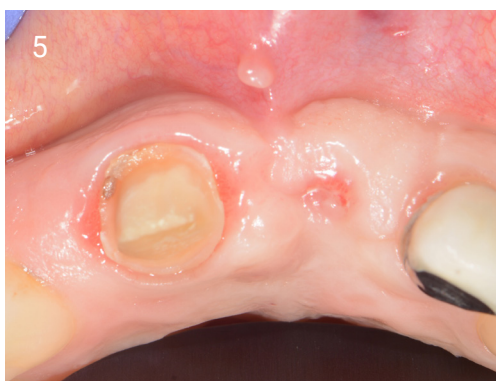2. Osteotomy in the ideal restorative position, not too palatal.



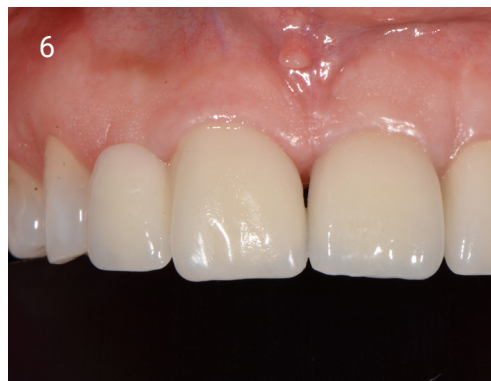3. Placement of 4.5 by 10 implant.



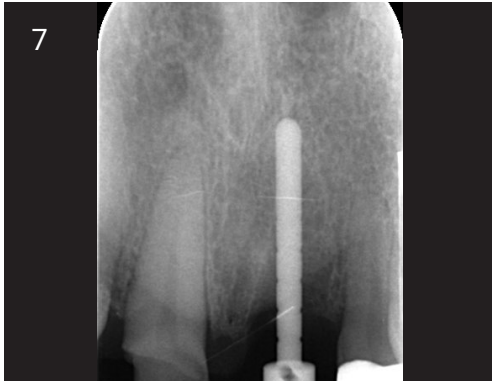4. Graft with EthOss®.



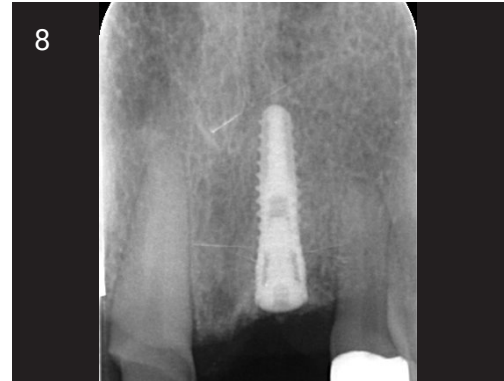5. Ready to load at 12 weeks.



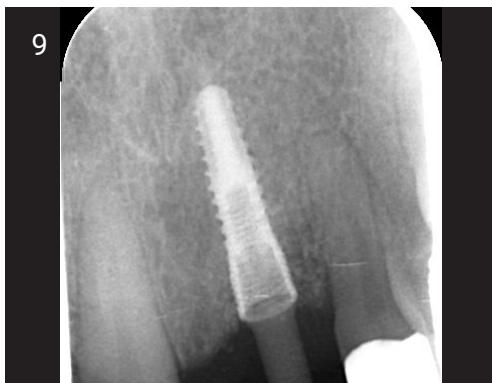6. Loaded at 9 months.



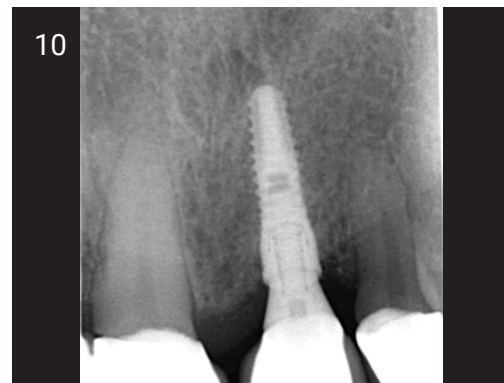7. Measuring tool to assess height.



8. Site grafted with EthOss®.



9. Osstell peg, 75 ISQ.



10. Loaded 9 months.